



---

## Interventions in Takayasu Arteritis- Two Case Studies in a Tertiary Health Care Centre

---

Vanaja Thakur<sup>1</sup>, Smit Shrivastava<sup>2</sup>, D.P. Lakra<sup>3</sup>

1- P.G. Resident 1- Professor and Head of the Department. of Cardiology, 3- Professor and Head of the Department of Medicine

Pt. J.M.M. Medical College Raipur

---

### Abstract

Takayasu arteritis, also known as pulseless disease, occlusive Thrombo-aortopathy, and Martorell syndrome,<sup>1</sup> is a chronic inflammatory arteritis affecting large vessels, predominantly the aorta and its main branches. Takayasu Arteritis is rare, but most commonly seen in Japan, South East Asia, India, and Mexico<sup>2</sup> accounting for 2.6 cases /million per year (3) with preponderance to females of 2<sup>nd</sup> to 3<sup>rd</sup> decade. In India, mean age is 24 years. 10% of patients are asymptomatic and rest presents with constitutional symptoms with headache being most common (50-57%) followed by malaise and arthralgia.

---

**Keywords:** Takayasu arteritis, Pulseless disease

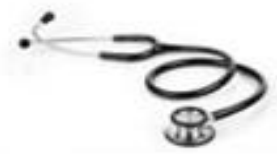---

### Case Study

The present study comprises of Two cases; who presented to the routine OPD, Department of Cardiology Pt. J. N. M. Medical College & B.R.A.M, Raipur, Chhattisgarh.

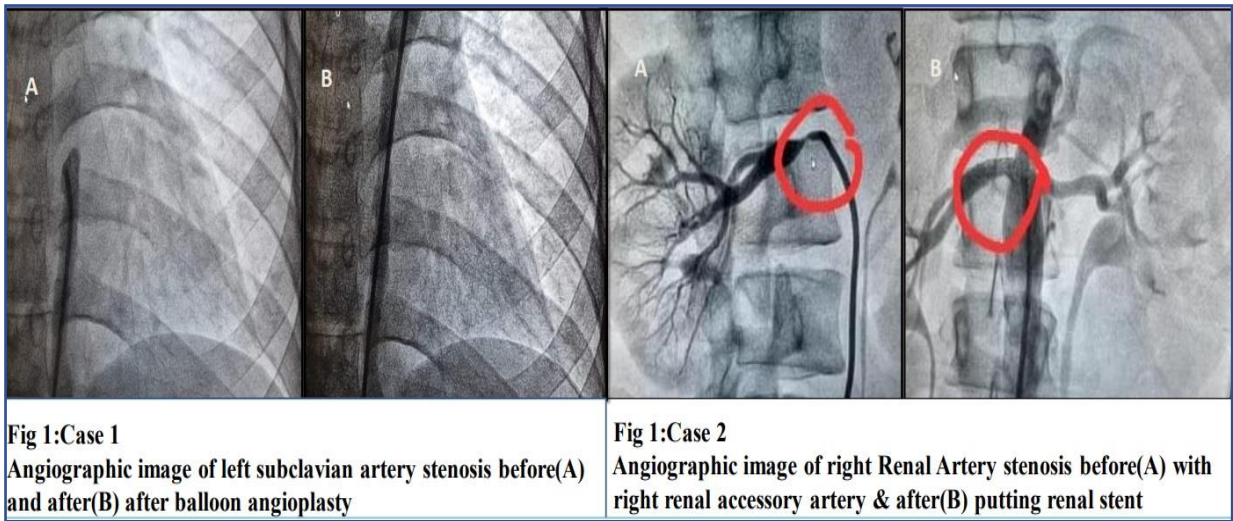
**Case 1:** 21yr /F presented with c/o claudication in both UL & LL since 2yrs and chest pain for 2 months. O/E -BP (R-UL)-190/90mm of Hg, (L-UL)-100/90mm of Hg, L- LL- 90mm of Hg & R-LL -90mmHg. P/R – feeble in L- Radial artery; R Radial artery-86/min, regular, hypervolemic & BL- LL Dorsalis Pedis artery was palpable. O/A- Continuous Murmur heard (collaterals). ECG- NSR. 2D-Echo-Dilated Aortic Root- 3.58cm, Moderate AR with eccentric jet striking the IVS. CT Angiogram- there is diffuse circumferential wall thickening noted in arch of aorta thoracic as well as abdominal aorta. The region of maximum stenosis at the level of thoracic aorta. There was diffuse wall thickening of left subclavian artery in whole of its course with multiple collaterals formation noted. CRP- 0.67. ESR-16 • Classified as – Type II B (Angiographic Classification Of TA-1994). Full-filling 6/6 criteria (ACR Case 2: •23/F presented with c/o on & off fever for 2 months.

**Case 2:** O/E- Hypertensive with difference in the contra-lateral UL with R- UL -170/112mm of Hg & R- L 144/104 mm of Hg, L- UL -155/95mm of Hg & L-LL -155/115 mm of Hg. Renal Doppler- s/o Right Renal Artery Stenosis. CT Angiogram- s/o Aorto-Arteritis with involvement of CT, SMA, Right-renal Artery & Accessory Right renal Artery- S/o Large Vessel Arteritis-? Takayasu Arteritis. Classified as- Type IV (Angiographic Classification Of TA-1994). Full-filling 5/6 criteria (ACR).



**Intervention**

Both the cases were managed with Antihypertensive (Amlodipine) and Steroids- Tab Dexamethasone in 1<sup>st</sup> case and Tab. Prednisolone 0.5mg/kg/day in 2<sup>nd</sup> case. Followed by Multiple Balloon Angioplasty in 1<sup>st</sup> case; which decreased the pressure gradient across the lesion of descending thoracic aorta from 100 to 40 mm of Hg with improvement in SBP from 190/100 to 160/75 2<sup>nd</sup> case was followed by Elective Rt Renal Artery Angioplasty and Renal Stenting.



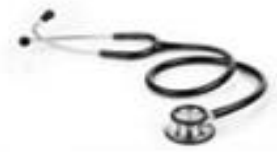**Differential Diagnosis**

It includes other causes of large vessel vasculitis: Inflammatory aortitis -syphilis, tuberculosis, lupus, rheumatoid arthritis, spondyloarthropathies, Behçet's disease, Kawasaki disease, and giant cell arteritis; Developmental abnormalities (coarctation of the aorta and Marfan syndrome); Aortic pathologies, such as ergotism and neurofibromatosis.

Most of these have specific features that enable diagnosis, but Tuberculosis has remained an important differential and possible etiological factor.

**Discussion**

There have been several studies highlighting the importance of achieving disease remission prior to revascularization. Fields et al. showed patients with active disease undergoing revascularization are more likely to require revision or develop progressive symptomatic disease at another site. Sadoun et al. demonstrated by multivariate analysis that biological inflammation at the time of revascularization was independently associated with the occurrence of arterial complications after a vascular procedure. According to the literature, open surgical treatment remains superior to endovascular intervention in the treatment of TA lesions yet associated with more complications. However, the recent results of endovascular procedures are with low peri- procedural complications and encouraging as well. Correlation of imaging with symptoms, adherence to the indications for



revascularization in TA, and ensuring disease activity is controlled prior to and following a procedure are key to the success of any vascular intervention, regardless of modality

### **Conclusion**

Takayasu's arteritis should be considered as one of the differential-diagnosis of the female patient coming with the non-specific complaints like head ache, malaise, fever and arthralgia. Bilateral B.P measurement should not be missed out in such cases, that may lead to the delayed diagnosis of the case. Renal artery stenosis is seen in 60% of the patients of TA, and should be kept in mind for its involvement.

### **References**

1. S L Johnston, R J Lock, M M Gompels Takayasu arteritis: a review; J Clin Pathol 2002;55:481-486
2. OLIVIA MANFRINI, RAFFAELE BUGIARDINI; Takayasu's arteritis: A case report and a brief review of the literature, Heart International / Vol. 2 no. 1, 2006 / pp. 66-71
3. Takayasu arteritis: a review S L Johnston, R J Lock, and M M Gompels.

**Publisher : Association for Welfare of Modern Medicine, Raipur**

**Editor : Dr Alok Shukla**

**Printer : Saluja Graphix**

Published by Association for Welfare of Modern Medicine, Raipur, 49 Celebrity, Neera Extension, Parthivi Nagar, Heerapur, Raipur  
Printed By Saluja Grafix, 108, 109, Dubey Colony, Vidhan Sabha Road, Mowa, Raipur